



The University of Tennessee  
College of Veterinary Medicine

# Can you help us?



## The "Fancy" Fund

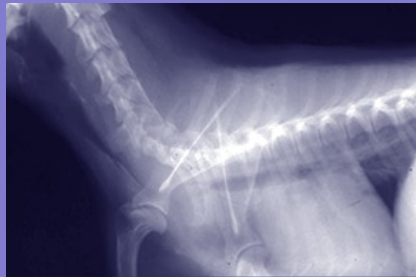for

### The Study of Collapsing Trachea in Small Breed Dogs

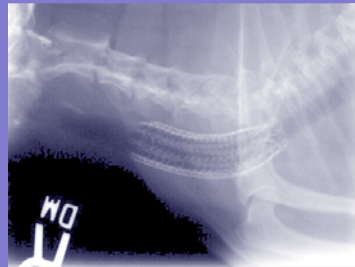
Tracheal collapse is a progressive, chronic, debilitating disease occurring primarily in middle-aged, toy-breed dogs. Pomeranians, poodles, Yorkshire terriers, and Chihuahuas are most commonly affected. Clinical signs of tracheal collapse include a chronic, nonproductive cough; exercise intolerance; and varying degrees of dyspnea (breathing difficulty). The cough often resembles a 'honking' sound. Clinical signs are exacerbated by obesity, excitement, or anxiety and may proceed to collapse and syncope (fainting).

Collapsing trachea is not a curable disease, but it can be managed. Medical management is usually tried first. Medical management includes weight loss, cough suppressants, bronchial dilators and sedation as needed to control anxiety and excitement. In many cases, medical management can result in long-term resolution of clinical signs, as long as other medical problems are appropriately addressed. In some cases, however, surgical treatment is required.


While numerous techniques have been developed for surgical correction of collapsed trachea, surgical placement of prosthetic C-shaped rings around the collapsed trachea has proved to be effective in many dogs. Permanently implanted, internal metallic stents are also being used notably in severe collapse of the thoracic trachea, as determined by radiography and endoscopy. Stents can be placed in both cervical and thoracic trachea, and many stented patients do very well long-term with only a slight cough. Some patients develop granulation tissue over the stent, and others may fracture the stent, resulting in re-collapse.



*Collapsed tracheae*



*Stented trachea*



*Stent in place*

#### Enclosed is my gift for the "Fancy" Fund

Amount enclosed:  \$1000  \$500  \$250  \$100  \$50  Other \$ \_\_\_\_\_

Make checks payable to the **University of Tennessee** (please indicate that the donation is for the "Fancy" Fund).

Name \_\_\_\_\_

Address \_\_\_\_\_

City \_\_\_\_\_ State \_\_\_\_\_ Zip \_\_\_\_\_

Gift by credit card:  Master Card  Visa  Discover

Account number: \_\_\_\_\_ Expiration date \_\_\_\_/\_\_\_\_/\_\_\_\_ Signature: \_\_\_\_\_

My gift will be matched by my employer and my completed gift form is enclosed.

On-line giving: go to [www.vet.utk.edu/giving/giving.shtml](http://www.vet.utk.edu/giving/giving.shtml)

**Thank you for your support!**



*In memory of "Mr. T"  
Photo: Linda Hicks*



The "Fancy" Fund  
The University of Tennessee  
College of Veterinary Medicine  
Office of Development, A102  
2407 River Drive  
Knoxville, TN 37996-4550

Thank you  
for your  
stamp.



*"Bingo"  
Photo: Greg Hirshoren*

Stents are very expensive. Also, proper application requires both endoscopy and fluoroscopy. One approach to collapsed trachea is to place rings on the cervical trachea to reduce expense and reserve stents for the thoracic trachea where rings are not feasible.

Drs. D.J. Krahwinkel and Mark Bohling are conducting studies on collapsing trachea at UT's College of Veterinary Medicine. They have obtained very encouraging results in a number of patients with the use of medical and surgical management, including prosthetic rings and internal stents.

The College of Veterinary Medicine seeks your help in support of continuing collapsing trachea studies and to assist in defraying the costs of stent surgeries. If you would like to donate, please complete and return the attached form with your check made payable to the University of Tennessee or with your credit card information.

**Thank you for your support!**



*"Sir Winston Baker"  
Photo: Judy Chisholm*

**UT**  
**College of Veterinary Medicine**

E18-1701-002-001-07 07-0085  
UT is an EEO/AA/Title VI/Title IX/Section 504/ADA/ADEA Institution.



*PortraitClassix.com*

*In memory of "Fancy"  
Photo: PortraitClassix.com*

# The "Fancy" Fund

for The Study of Collapsing Trachea  
in Small Breed Dogs